

***'Opening wedge high tibial osteotomy using 3D biomodelling  
Bonelike® macroporous structures - case report'***

Journal of Materials Science: Materials in Medicine (2007) 18: 2377-2382

M. Gutierrez, A.G. Dias, M.A. Lopes, N. Sooraj Hussain, A.T.Cabral, L. Almeida, J.D. Santos

## Opening wedge high tibial osteotomy using 3D biomodelling Bonelike<sup>®</sup> macroporous structures: case report

M. Gutierrez · A. G. Dias · M. A. Lopes · N. Sooraj Hussain ·  
A. T. Cabral · L. Almeida · J. D. Santos

Received: 1 May 2006 / Accepted: 12 September 2006 / Published online: 14 June 2007  
© Springer Science+Business Media, LLC 2007

**Abstract** Two synthetic calcium phosphates in porous wedge shape, Bonelike<sup>®</sup> and a commercial HA/ $\beta$ -TCP biphasic material, were used as an alternative to bone autografts and allografts in the treatment of medial compartment osteoarthritis of varus knees. The structure of Bonelike<sup>®</sup> has a 3D architecture that is computer controlled, and a composition that mimics the mineral composition of natural bone. The HA/ $\beta$ -TCP biphasic material used as a control material in this study was prepared using conventional foaming based methods. No signs of inflammatory reactions were observed post-operatively for both materials. After 4 months signs of fusion at the osteotomy site and good integration of the implanted wedges were observed, showing good mechanical resistance. Concerning the final correction attained, the left knee revealed a satisfactory valgus of 10°, but the right one only had a final value of 6°. The clinical evaluation using International Knee Score (IKS) showed good outcome in all parameters with complete

range of motion in both knees and climbing stairs without crutches with only slight pain.

### Introduction

Dealing with bone defects is a permanent challenge in orthopaedic and trauma field. A valgus tibial osteotomy has been selected as an efficient method of treatment for patients with medial compartment osteoarthritis in varus knees [1–4]. Studies have shown that there exists some degree of cartilage regeneration after this procedure [5–7] even without chondrocyte implantation.

Lateral closing wedge high tibial osteotomy technique (HTO) has been so far the most used surgery to solve this problem. Nevertheless, in order to avoid the peroneal osteotomy and obtain more accurate correction of varus deformity, a technique of medial opening wedge tibial osteotomy has been introduced. The later technique has many advantages compare with the former one. Opening wedge tibial osteotomy is a simple and less invasive technique, and the fixation is accomplished easily by means of metal plates and screws. Later, if conversion to a total knee arthroplasty is needed, then the procedure is also simplified.

A fashioned wedge with the exact angle for the opening required can be inserted in the osteotomy site, allowing not only coronal but also sagittal corrections. However, opening wedge HTO has limitations such as the risk of collapses, with loss of correction and non-union [1, 2, 4, 8, 9].

The gap created by the osteotomy may be filled with autograft or synthetic materials [10]. An autograft substitute, most specifically iliac crest cortico-cancellous graft,

---

M. Gutierrez · A. T. Cabral · L. Almeida  
FMUP – Faculdade de Medicina da Universidade do Porto,  
Hospital de São João, Largo Hernâni Monteiro, Porto 4200,  
Portugal

A. G. Dias · M. A. Lopes · N. S. Hussain ·  
J. D. Santos  
FEUP – Faculdade de Engenharia da Universidade do Porto, Rua  
Dr. Roberto Frias, Porto 4200-465, Portugal

A. G. Dias · M. A. Lopes · N. S. Hussain ·  
J. D. Santos (✉)  
Laboratório de Biomateriais, Instituto de Engenharia Biomédica  
(INEB), Rua do Campo Alegre 823, Porto 4150-180, Portugal  
e-mail: jdsantos@fe.up.pt

is considered the most successful bone filling because of its osteoconductive, osteoinductive and osteogenic properties. However, autograft substitutes showed some drawbacks related to the donor site and require a second surgery. To overcome the disadvantages of the autografts, synthetic bone substitutes morphologically adapted to the host site are starting to be used in several orthopaedic applications. Pre-shaped wedges designed for specific applications simplified the surgery procedure as well as add some mechanical stability. The synthetic substitutes have been reported as bioactive and can support bone growth and remodelling, which may lead to faster full weight-bearing after open wedge valgus HTO [11–15].

Three-dimensional porous scaffolds seem to be a good option for opening wedge HTO, as they offer a framework for new bone tissue formation and anchorage by providing surface and volume, that will allow cell ingrowth and an accurate cell distribution throughout the porous structure [16–19].

Recently, the authors have reported the potential of a composite material, registered as Bonelike<sup>®</sup>, as a synthetic bone graft in animal models and in implantology and oral maxillofacial applications comparing with the commercially available pure HA [20–24]. In the present study, two materials prepared in different ways, computer controlled 3D architecture fabrication and conventional based techniques, were used as a bone substitutes, Bonelike<sup>®</sup> and a HA/ $\beta$ -TCP biphasic material, respectively. The 3D architecture computer-controlled fabrication techniques, known as rapid prototyping (RP), have significant advantages over conventional based fabrication methods. Although conventional methods hold great success in preparing scaffolds for bone applications, the computer-controlled fabrication techniques promises rapid solutions in automating scaffold production as well provide several advantages such as easy processing, macro shape and structural design, which leads to good compressive strength [14, 25, 26]. The purpose of this work was to evaluate the performance of two porous wedge materials with different structures in the treatment of medial compartment osteoarthritis varus knee.

## Materials and methods

### Bonelike<sup>®</sup> composite preparation

Bonelike<sup>®</sup> composite powders were prepared as described in previous studies [27–29]. Briefly, a calcium phosphate glass with a composition of 15CaO–65P<sub>2</sub>O<sub>5</sub>–10CaF<sub>2</sub>–10Na<sub>2</sub>O (mol%) was prepared using reagent grade chemicals. The glass was obtained by melting in a platinum crucible at 1,450°C for 2 h. The prepared glass was

crushed in an agate mortar and sieved to a granule size below 75  $\mu$ m. The Bonelike<sup>®</sup> composite was then obtained by mixing 4 wt.% wt of the obtained glass with phase pure laboratory prepared hydroxyapatite (HA) in isopropanol. The mixture was dried for 24 h at 60 °C and sieved to less than 75  $\mu$ m.

### Wedges preparation

The Bonelike<sup>®</sup> composite powders were first uniaxially pressed at 120 MPa to obtain dense block shaped compacts followed by isostatic pressing. Then, RP technology was used to build a porous structure from the block shaped compacts directly from CAD-based data according to the specific construction needs. The computer-aided manufacturing technique allows us to produce porous wedges as shown in Fig. 1. Finally, the obtained porous Bonelike<sup>®</sup> wedges were sintered at 1,300 °C during 1 h. The dimensions of the wedges, required for this particular case, were: 40 × 19 mm, the tip and the base height were 4 and 12 mm, respectively (Fig. 1).

The commercial wedges used as a control material, were a biphasic ceramic composed of 65% of HA and 35% of tricalcium phosphate ( $\beta$ -TCP). As reported in the literature, this ceramic has been prepared using the conventional method, i.e. macroporosity is formed in the structure of the ceramic body by a foaming technique [30].

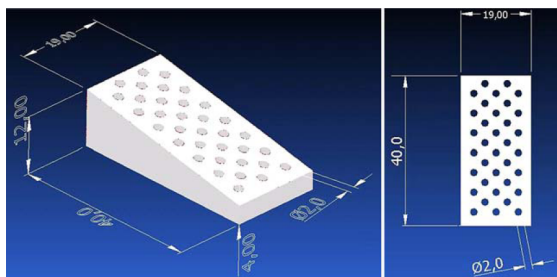
### Materials characterization

For X-ray diffraction analysis, samples were ground to fine powders of Bonelike<sup>®</sup>, and analysed using a Siemens D 5000 diffractometer with flat plate geometry and CuK $\alpha$  radiation. Data was collected from 10 to 80° (2 $\theta$ ), with a step size of 0.02° and a counting time of 2 s per step. Quantitative phase analysis was performed by the Rietveld method using General Structure Analysis Software (GSAS, Los Alamos National Laboratory).

### Clinical case

In June 2004, a 58-years old male patient (AMS, truck driver) was evaluated in the Orthopaedic Department of Hospital de São João (Porto, Portugal), complaining of bilateral knee pain, specially in the left side, for the last 4 years. The character of the pain was mechanical, predominantly localized in the medial compartment, but also with some femuropatellar complains. The medication and physiotherapy have provided only partial relieve of the symptoms. The patient referred that, when he was 40 years old, he was submitted to an open medial meniscectomy in the left knee.

**Fig. 1** Top and bottom view of Bonelike<sup>®</sup> wedge. The length of the edge is 40 mm, the thickness is 19 mm and the tip and base height is 4 and 12 mm, respectively. Porous diameter is 2.0 mm



*Clinical and radiographic evaluation*

The patient was preoperatively evaluated according the standard protocol of Orthopaedic Department of Hospital de São João (Porto, Portugal) that is the International Knee Score (IKS). The physical examination showed: bilateral genuum varum, with quadriceps atrophy, a parapatellar scar from the previous meniscectomy in the left knee, good range of motion, small amount of intraarticular fluid, positive valgus stress test, but negative Mc Murray and anterior drawer test.

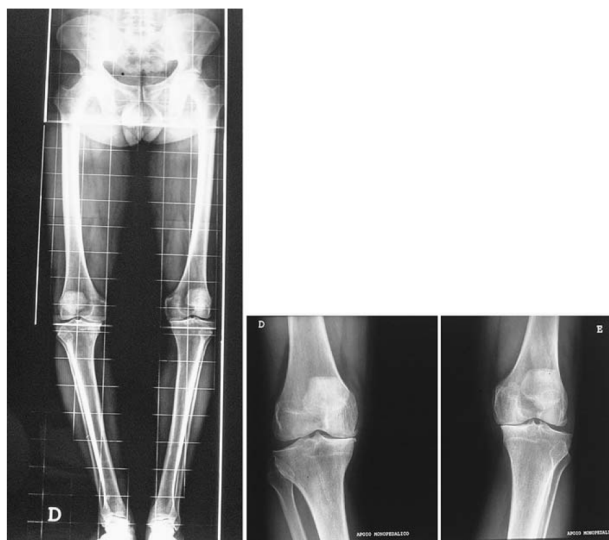The radiological procedures included anteroposterior knee view standing on each leg; lateral view with 30°

flexion; skyline views and hip-knee-ankle radiographs, with the patient standing on both legs, which allowed determining the global alignment of the limb and performing the operative planning in order to obtain an accurate correction. The radiographic examinations showed a bilateral osteoarthritis, mainly in the medial compartment (grade II–III—modified Ahlback) and a varus of 6° in the left and 10° in the right knee (Fig. 2).

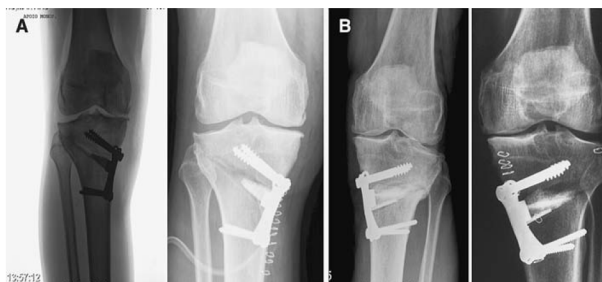*Operative technique*

An opening wedge osteotomy was planned to obtain 2 or 3° of hypercorrection in the alignment of both knees that is 9

**Fig. 2** Pre-operative X-ray show 6° of anatomical varus in the left and 10° in the right leg



**Fig. 3** Post-operative X-ray after 8 weeks of right knee treated with Bonelike<sup>®</sup> composite (A) and left knee treated with commercial HA/TCP (B)



or 10° valgus. First, the patient was submitted to a valgus osteotomy in the left knee with addition of a 12° medial wedge of a commercial HA/ $\beta$ -TCP biphasic material. About eight months later the same surgical procedure was applied to the right knee using the Bonelike<sup>®</sup> composite material. In both cases, the medial wedge opening side was stabilized by means of a Puddu plate and screws to avoid subsequent displacement of the wedge (Fig. 3). The post-operative period was normal, with no signs of inflammatory reaction. Total weight bearing was allowed at 4 weeks.

### Results and discussion

Opening osteotomy techniques are efficient in the correction of tibial varus deformity, sparing bone tissue, avoiding shortening, caused by osteotomies with bone wedge resection [1–9]. Two approaches can be followed in terms of the clinical use of bone grafts, granules or pre-shaped wedges. The granules have a high surface area and cover a large area of cancellous bone in the open gap and provide a loose matrix for bone ingrowth. However, the pre-shaped wedges improve the ease of handling as well as might add some mechanical stability to the implant graft. In the case of pre-shaped wedges, to obtain bone ingrowth through the material's structure, the macroporous scaffold must show pores diameter ranging from 100 to 1,000  $\mu\text{m}$ . This structure allows for cell ingrowth and neovascularisation [13–15, 18, 19, 26, 31].

Several authors report the use of different bone substitutes, such as acrylic bone cement, HA and tricalcium phosphate, in tibial osteotomies [31–34]. Although acrylic bone cement is clinically used, it shows some limitations regarding absence of resorption, porosity and osteointegration. Essentially, its use only provides initial stability. The use of porous HA resulted in excellent follow-up results, showing bone ingrowth into the pores throughout the implantation periods. These studies showed a direct

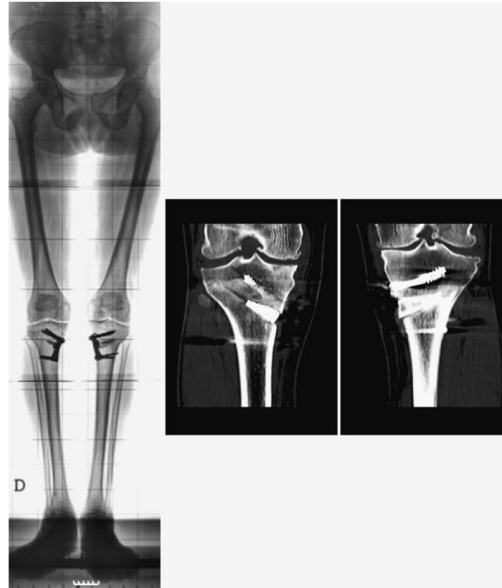relation among three factors, bone ingrowth, implantation periods and porous diameter. However, the radiodensity of HA was maintained for a long time in radiographic follow-up, which prove its lack of resorption [34, 35]. Conventionally fabricated porous  $\beta$ -TCP have shown to be osteoconductive and resorbable, however its application in opening wedge osteotomy has usually been associated with internal or external fixation due to lack of structural reliability [31, 32] and therefore a rigid fixation method is required to provide stability of the implant graft and reduce the risk of non-union and collapses at the osteotomy site as well as to reduce the long post-operative immobilization of the patients [36].

In the present work, the clinical performance of two bioactive materials that were applied in open wedge osteotomies was evaluated. For both materials, the post-operative period was normal, with no signs of inflammatory reaction. About four months after the surgery the radiological evaluation showed signs of fusion at the osteotomy site and good integration of both implanted grafts. The correction achieved in the left knee revealed a satisfactory valgus of 10°, but the right one only had a final value of 6°, as shown in Fig. 4. The clinical evolution was also favourable with the IKS evaluation performed at 4 months post-operative showing a good outcome (complete range of motion in both knees, only slight pain on climbing stairs and no use of crutches).

The commercial ceramic used was a biphasic one, composed of 65% of HA and 35% of tricalcium phosphate. Literature confirms its application in orthopaedic and trauma surgery, revealing a good biocompatibility [30]. In the first osteotomy, where this material was used, showed good results from clinical and radiological point of view. The second intervention that was performed in the right knee using Bonelike<sup>®</sup> material, showed radiological osteointegration and consolidation after 4 months.

Besides the ability of reinforcing the structure of HA, the addition of  $\text{CaO-P}_2\text{O}_5$  based glass into the HA structure leads to the formation of secondary phases,  $\alpha$ - and  $\beta$ -TCP.

**Fig. 4** X-ray and tomogram taken after 12 months of left osteotomy and 4 months after of right osteotomy



Their percentage is dependent upon the sintering treatment, content and the composition of the glass added [27–29, 37, 38]. Due to the presence of HA and  $\alpha$ - and  $\beta$ -TCP in the structure of Bonelike<sup>®</sup> composite, which are known to be biodegradable and bioresorbable phases, a local enrichment in Ca and P in the physiological environment occurs, which stimulates new bone formation helping in osteointegration of Bonelike<sup>®</sup> composite as well as improve the mechanical strength.

Bonelike<sup>®</sup> wedge was prepared by 3D biomodelling, which is a technique that allows for complete structural control of the synthetic graft, automation of the manufacturing process and high precision of the pore size and pore distribution. All these parameters are known to play a fundamental role in the structural reliability of the synthetic graft and accounts for the higher compressive strength than those grafts that are prepared by conventional slip casting and foaming techniques. From radiological examination it was evident that no graft displacement, distortion or fracture occurred, which should be attributed to the high precision of the manufacturing process.

This clinical case report confirms other previous studies that had shown that Bonelike<sup>®</sup> is rapidly osteo-integrated after implantation in maxillofacial surgery and implantology [20, 21]. In orthopaedic applications,

radiological, histological histomorphometric measurements and scanning electron microscopy have previously demonstrated that Bonelike<sup>®</sup> is highly bioactive and it resorbs at a rate that is compatible with the new formation rate. The possibility of applying 3D Biomodelling techniques to manufactured high-precision macropores structures for opening wedge tibial osteotomy opens-up new areas of application of Bonelike<sup>®</sup> in the orthopaedic field.

**Acknowledgements** The authors express their grateful thanks to the FCT – Fundação para a Ciência e a Tecnologia for their support in this work through the project “New generation of bioactive and bioresorbable materials for bone regenerative surgery using 3D biomodelling” POCTI/CTM/59091/2004 and also through Post-Doctoral grants SFRH/BPD/14969/2004 and SFRH/BPD/6010/2001.

## References

1. R. D. A. GAASBEEK, R. T. C. WELSING, N. VERDONS-CHOT, W. J. RIJNBERG, C. J. M. van LOON and A. van KAMPEN, *Knee Surg. Sports Traumatol. Arthrosc.* **13**(8) (2005) 689
2. W. N. SCOTT and H. D. CLARKE, *Orthopedics* **27**(9) (2004) 975
3. P. VIROLAINEN and H. T. ARO, *Arch. Orthop. Trauma Surg.* **124**(4) (2004) 258

4. J. M. WRIGHT, H. C. CROCKETT, D. P. SLAWSKI, M. W. MADSEN and R. E. WINDSOR, *J. Am. Acad. Orthop. Surg.* **13**(4) (2005) 279
5. Y. FUJISAWA, K. MASURA and S. SHIOMI, *Clin. Orthop. North Am.* **10** (1979) 585
6. S. ODENBRIDGE, N. EGUND, A. LINDSTRAND, L. S. LOHMANDER and H. WILLEN, *Clin Orthop.* **277** (1992) 210
7. T. KOSHINO, S. WADA, Y. ARA and T. SAITO, *Knee* **10** (2003) 229
8. P. HERNIGOU, *Knee* **9**(1) (2002) 15
9. S. HOELL, J. TUTTMOELLER, V. STOLL, S. FUCHS and G. GOSHEGER, *Arch. Orthop. Trauma Surg.* **125**(9) (2005) 638
10. R. R. BETZ, *Orthopedics* **25**(5) (2002) S561
11. R. Z. LEGEROS, *Clin. Orthop. Relat. Res.* **395** (2002):81
12. T. STEFFEN, T. STOLL, T. ARVINTE and R. K. SCHENK, *Eur. Spine J.* **10** (2001) S132
13. T. M. G. CHU, D. G. ORTON, S. J. HOLLISTER, S. E. FEINBERG and J. W. HALLORAN, *Biomaterials* **23**(5) (2002) 1283
14. D. W. HUTMACHER, M. SITTINGER and M. V. RISBUD, *Trends Biotechnol.* **22**(7) (2004) 354
15. J. R. JONES, L. M. EHRENFRIED and L. L. HENCH, *Biomaterials* **27**(7) (2006) 964
16. O. GAUTHIER, J. M. BOULER, E. AGUADO, P. PILET and G. DACULSI, *Biomaterials* **19**(1–3) (1998) 133
17. J. X. LU, B. FLAUTRE, K. ANSELME, P. HARDOUIN, A. GALLUR, M. DESCAMPS and B. THIERRY, *J. Mater. Sci. Mater. Med.* **10**(2) (1999) 111
18. M. MARTINA, G. SUBRAMANYAM, J. C. WEAVER, D. W. HUTMACHER, D. E. MORSE and S. VALIYAVEETIL, *Biomaterials* **26**(28) (2005) 5609
19. L. MORONI, J. R. de WIJN and C. A. van BLITTERSWIJK, *Biomaterials* **27**(7) (2006) 974
20. F. Duarte, J. D. Santos and A. Afonso, *Adv. Mater. Forum* **455–456** (2004) 370
21. J. V. LOBATO, N. S. HUSSAIN, C. M. BOTELHO, A. C. MAURICIO, J. M. LOBATO, M. A. LOPES, A. AFONSO, N. ALI and J. D. SANTOS, *Thin Solid Films*, **515**(1) (2006) 279
22. M. GUTIERRES, N. S. HUSSAIN, A. AFONSO, L. ALMEIDA, T. CABRAL, M. A. LOPES and J. D. SANTOS, *Bioceramics* **17** (2005) 1041
23. J. V. LOBATO, N. S. HUSSAIN, C. M. BOTELHO, J. M. RODRIGUES, A. L. LUÍS, A. C. MAURÍCIO, M. A. LOPES and J. D. SANTOS, *Key Eng. Mater.* **284–286** (2005) 877
24. M. A. LOPES, J. D. SANTOS, F. J. MONTEIRO, C. OHTSUKI, A. OSAKA, S. KANEKO and H. INOUE, *J. Biomed. Mater. Res.* **54** (2001) 463
25. K. F. LEONG, C. M. CHEAH and C. K. CHUA, *Biomaterials* **24**(13) (2003) 2363
26. D. W. HUTMACHER, *J. Biomater. Sci. Polym. Ed.* **12**(1) (2001) 107
27. J. SANTOS, G. HASTINGS and J. KNOWLES, Sintered hydroxyapatite compositions and method for the preparation thereof. Worldwide Application (PCT), Patent No. 1 189 851, 1999
28. M. A. LOPES, J. D. SANTOS, F. J. MONTEIRO and J. C. KNOWLES, *J. Biomed. Mater. Res.* **39**(2) (1998) 244
29. M. A. LOPES, J. C. KNOWLES and J. D. SANTOS, *Biomaterials* **21**(18) (2000) 1905
30. C. SCHWARTZ, P. LISS, B. JACQUEMAIRE, P. LECESTRE and P. FRAYSSINET, *J. Mater. Sci. Mater. Med.* **10**(12) (1999) 821
31. W. L. W. van HEMERT, K. WILLEMS, P. G. ANDERSON, R. J. van HEERWAARDEN and A. B. WYMENGA, *Knee* **11**(6) (2004) 451
32. R. D. A. GAASBEEK, H. G. TOONEN, R. J. van HEERWAARDEN and P. BUMA, *Biomaterials* **26**(33) (2005) 6713
33. P. HERNIGOU and W. MA, *Knee* **8**(2) (2001) 103
34. T. KOSHINO, T. MURASE and T. SAITO, *J. Bone Joint Surg. Am.* **85A**(1) (2003) 78
35. T. KOSHINO, T. MURASE, T. TAKAGI and T. SAITO, *Biomaterials* **22**(12) (2001) 1579
36. F. ZHIM, G. Y. LAFLAMME, H. VIENS, K. SAIDANE and L. YAHIA, *Clin. Biomech.* **20**(8) (2005) 871
37. M. A. LOPES, F. J. MONTEIRO and J. D. SANTOS, *Biomaterials* **20**(21) (1999) 2085
38. M. A. LOPES, F. J. MONTEIRO and J. D. SANTOS, *J. Biomed. Mater. Res.* **48**(5) (1999) 734